

**DATE PRESENTING CLINICAL SIGNS**

4/4/2022 History: Periodic vomiting and diarrhea- mostly resolved.

**PATIENT**

Levi Tallagsen

Current Medications: Sentinel, Simparica, Thyro-tabs 0,4mg BID (new dosage based on labs).  
 Lab Results: CBC- mature lymphocytosis, T4 (post pill) 6.6. New genetic test: NuQ Cancer Screen 9.5 (9.1-57.4) this is a genetic test for HAS in at-risk breeds.  
 Date of Previous IntraPet Ultrasound: No previous.  
 Sedation: Not required to complete full diagnostic ultrasound.  
 Stat Report: Not requested.

**SPECIES**

Canine Imaging Performed By: Rachel Brillhart, RDMS.

**BREED**

Golden Retriever

**ULTRASONOGRAPHIC EXAMINATION OF THE ABDOMEN****SEX**

Neutered Male

**Urinary System**

The urinary bladder, trigone, and pelvic urethra are normal in thickness and the mucosal surface is smooth. The bladder lumen is moderately distended with anechoic urine. No masses, inflammatory changes or calculi are observed. Ureteral papillae and visualized portion of the proximal urethra, visible to a depth of 2 cm, are normal.

**AGE**

1/28/2014

The prostate is normal in size (1.13 cm in width) and shape. Parenchyma is homogenous. The prostatic urethra appears normal without evidence of dilation or obstruction.

**WEIGHT**

84.2 lbs

The left kidney presented normal size (8.12 cm in length); normal shape and architecture with smooth peripheral margins. There is a normal 1:3 cortex to medulla ratio with normal corticomedullary distinction. There is no evidence of pyelectasia, nephroliths, infarcts or hydroureter. Renal vasculature is normal.

**INTERPRETED BY**

Andrea Nicastro, DMV,  
 Diplomate DACVIM  
 (Small Animal  
 Internal Medicine)

The right kidney presented normal size (7.38 cm in length); normal shape and architecture with smooth peripheral margins. There is a normal 1:3 cortex to medulla ratio with normal corticomedullary distinction. There is no evidence of pyelectasia, nephroliths, infarcts or hydroureter. Renal vasculature is normal.

**HOSPITAL NAME**

Eastern Animal  
 Hospital

**Adrenal Glands**

The left adrenal gland is normal size (0.77 cm at cranial pole) (0.68 cm at caudal pole) (3.09 cm in length); normal shape; homogenous parenchyma. The glandular echogenicity and detail are unremarkable. Capsule, cortex, and medullary definition are normal. The phrenicoabdominal vein and surrounding vasculature are normal.

**REFERRING VET**

Dr. Kaufman

The right adrenal gland is normal size (0.80 cm at cranial pole) (0.75 cm at caudal pole) (3.55 cm in length); normal shape; homogenous parenchyma. The glandular echogenicity and detail are unremarkable. Capsule, cortex, and medullary definition are normal. The phrenicoabdominal vein and surrounding vasculature are normal.

**INVOICE**

10680

**Spleen**

The spleen is normal in size with a normal capsular contour. The parenchyma is diffusely mottled, bordering on a "moth-eaten" appearance. No focal lesions are observed. Splenic vasculature is normal.

**Liver**

The liver is subjectively normal in size with normal curvilinear peripheral contours. The parenchyma is hypoechoic relative to the spleen and subtly heterogenous in appearance. No distinct focal lesions are

observed. There is a questionable increase in portal markings. Hepatic vasculature and intrahepatic biliary tracts are of normal volume with no evidence of congestion.

The gall bladder lumen is moderately distended. The wall is thin and smooth. Luminal contents are anechoic. The cystic and common bile ducts are normal.

### ***Gastrointestinal***

The stomach and intestine are free of stasis and exhibit normal peristaltic activity. The gastric lumen is not distended. The gastric wall and pylorus are normal in thickness with a normal layering pattern. The small intestinal lumen is not dilated. The small intestinal wall thickness is normal with a normal layering pattern and appropriate mural detail. Discreet masses are not identified. The colonic wall is normal. No obstructive or overt infiltrative disease is noted.

### ***Pancreas***

The region of the pancreas is isoechoic relative to surrounding omental fat. No obvious parenchymal abnormalities are observed. There is no evidence of regional inflammation or effusion.

### ***Free Abdomen***

The peritoneal cavity is normal. There is no evidence of inflammation or effusion. A 4.32 cm sublumbar lymph node is visualized. The node is normal in shape and echogenicity.

### ***Other***

A brief echocardiogram reveals no evidence of pericardial effusion or obvious right atrial/auricular mass.

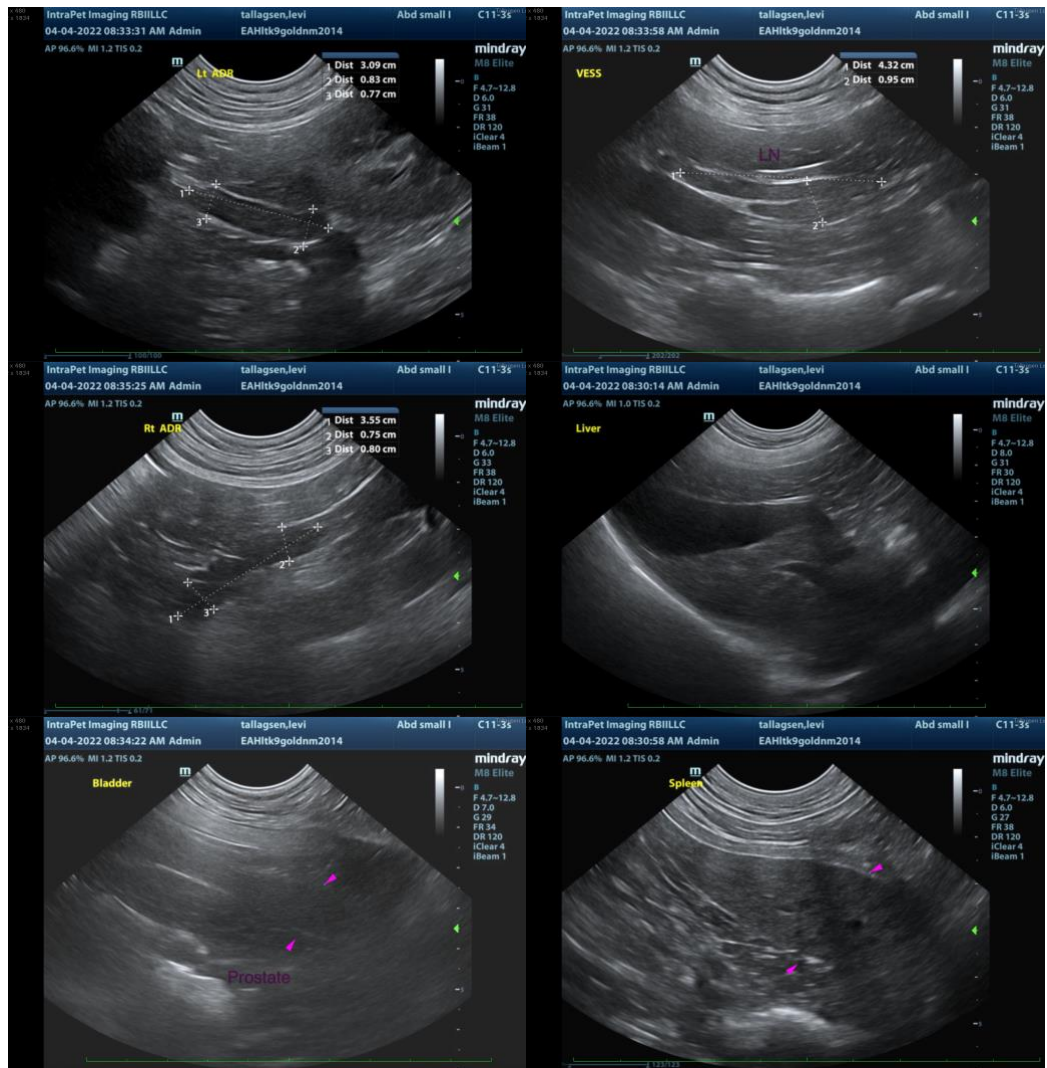
## **ULTRASONOGRAPHIC FINDINGS**

### **Primary Findings**

- The splenic parenchyma changes could be consistent with infiltrative neoplasia (i.e., round cell tumor). Alternatively, a benign process such as lymphoid hyperplasia, extramedullary hematopoiesis or splenitis is also possible.
- The prominent sublumbar lymph nodes are mostly reactive with a lower possibility of infiltrative neoplasia.
- The hepatic parenchymal changes could be consistent with a benign age-related process (i.e., regenerative nodular hyperplasia and/or vacuolar hepatopathy). Infiltrative or inflammatory disease are also possible but considered less likely given the normal liver values.

## **INTERPRETATION OF THE FINDINGS & FURTHER RECOMMENDATIONS**

- Given the mature lymphocytosis, consider a repeat CBC with a clinical pathology review. Also consider chest x-rays (three-view) to assess for occult neoplasia in the chest, as well as fine-needle aspirates of the spleen +/- liver, if clotting status is appropriate.
- Given the GI signs, other considerations include a fecal evaluation for ova and Giardia, prophylactic deworming with fenbendazole +/- more advanced GI workup (i.e., -resting cortisol level, hypoallergenic diet trial and GI biopsies).



The information and recommendations provided are based on the images presented by the referring veterinarian/sonographer. No evaluation can be communicated regarding pathology that was not visible in the image/video clips provided.

Thank you for this referral. If the clinical or image interpretation does not parallel your findings or if I can be of any further assistance, please contact me.

**Andrea Nicastro, DVM, Diplomate DACVIM (Small Animal Internal Medicine)**  
[info@SonoPath.com](mailto:info@SonoPath.com)